

Struma ovarii in combination with increased levels of CA125 and ascites: Case report and review of the literature

Kougioumtsidou Anna, Kougioumtsidou Niki, Athanasopoulou Maria, Pados George, Tarlatzis Vasileios

1st Department of Obstetrics and Gynecology, Aristotelian University of Thessaloniki,
Papageorgiou hospital, Thessaloniki, Greece

Correspondence

Kougioumtsidou Anna, 1st Department of Obstetrics and Gynecology, Aristotelian University of Thessaloniki,
Papageorgiou hospital, GR-54623, Thessaloniki, Greece. **E-mail:** akougioum@gmail.com

Abstract

Ovarian goiter is a rare tumor of the ovary that is characterized by a presence of thyroid tissue in the ovary and occupies more than 50% of the total mass of the tumor. It is accompanied by ascites in the 1/3 of cases. The combination of struma ovarii, ascites and increased levels of CA125 is extremely rare. We report a case of a 77 years old woman with ascites, a big mass on the left ovary and increased levels of CA125, which are signs and symptoms of

malignant tumor of the ovary. The patient underwent surgical removal of tumor with rapid remission of the ascites and decrease of the levels of CA125. Struma ovarii can imitate a malignant tumor of the ovary, especially when it is accompanied by ascites and increased levels of CA125.

Key words: ovarian goiter; struma ovarii; ascites; thyroid tissue; CA125

Ovarian goiter is a rare type of tumor of the ovaries, that constitutes 0.3-1.2% of all the ovarian luteomas and 2.7% of the dermoid tumors of the ovary¹. It is characterized by a presence of thyroid tissue in the ovary that occupies more than 50% of its total mass. Struma ovarii is usually benign, but in rare occasions (5%) we notice a malignant change². Preoperative diagnosis is difficult, since there are no notable symptoms and points of the disease. Patients usually come in with asymptomatic ovarian mass, widespread abdominal pain, distension of the abdominal walls due to ascites and abnormal ovarian bleeding. While ascites appears in 1/3 of the cases³, there is rarely an additional increase of the CA125. Few cases of struma ovarii have been reported

to be accompanied by a pseudo-Meigs syndrome. Thyrotoxicosis appears in 5% of the cases⁴.

A 77 years old woman is presented with ascites, ovarian mass, increased levels of CA125, without symptoms of hyperthyroidism. This case was treated at first as a malignant tumor of the ovary and was submitted to exploratory laparotomy surgery.

Case report

The case of a 77 years old woman is reported, in menopause (since 20 years) with a maternity medical history of 8 natural childbirths and 3 spontaneous abortions. From the personal history, the following are reported: appendectomy, coronary disease, heart failure under treatment and mild degree of ob-

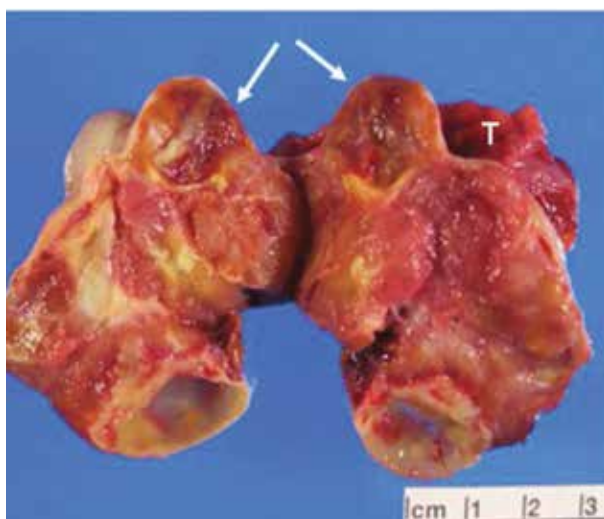


Figure 1. Macroscopic view of the struma ovarii

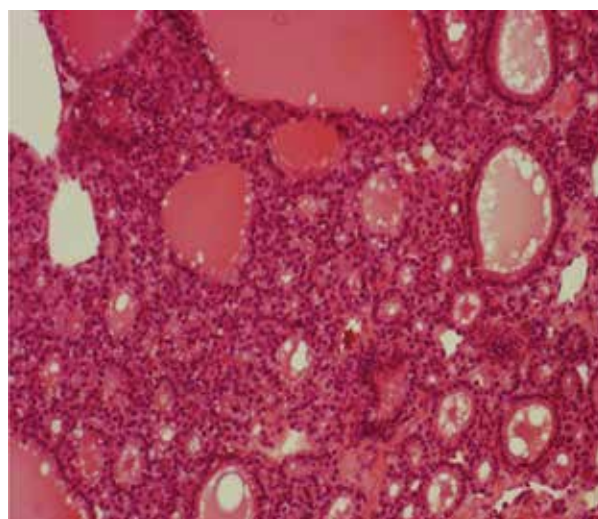


Figure 2. Typical microscopic presentation of struma ovarii

structive pulmonary disease. The woman came in the outpatient clinic of the First Department of Obstetrics and Gynecology of the Aristotle University of Thessaloniki at Papageorgiou hospital, due to a two month's widespread abdominal pain and meteorism. During the physical examination it was detected that there was distension of the abdominal walls due to a palpable mass on the lower abdomen, on the anatomical position of the left adnexal region. The woman was admitted to our clinic for further examination. An abdominal ultrasound and a computed tomography of the upper and lower abdomen and the retroperitoneal space were conducted, where moderate degree of ascites and cystic mass to the space of distribution of the left ovary, with dimensions 7 x 5 x 4 cm, were detected.

The uterus was of normal size while the right adnexum was not depicted. In the rest of the intra-abdominal organs (liver, spleen, kidneys and adrenal glands) no pathological findings were detected. During the examination, a computed tomography of the chest was done, which showed absence of pleural effusion and absence of swollen mediastinal and portal lymph nodes. In the lab test, an increased rate of CA125 (264.0 U/ml) was observed, while CEA (1.0 U/ml), CA15 - 3 (15.6 U/ml), CA19 - 9 (19.25 U/ml), AFP (4.83 U/ml) were within normal limits. The

rest of the test had no pathological findings.

The patient underwent exploratory laparotomy. Approximately 500ml of a tinged yellow ascetic fluid was found and was sent for a cytology examination. A complete hysterectomy on both anexasides, a removal of a multiple space-occupying tumor on the left ovary (Figure 1) and a partial omentectomy were conducted. No traces of intraperitoneal spread of the disease were noticed.

The histopathological examination of the tumor presented struma ovarii (thyroid tissue of follicles of various diameter filled with colloid) (Image 2), without omental cakes and without malignant cells at the cytology examination of the ascetic fluid. The uterus, the right ovary, the right salpinx and the left salpinx were examined with no pathological findings.

The postoperative course was smooth and the check of the functioning of the thyroid gland two days later was normal. The patient was discharged the seventh postoperative day. The recheck two months later showed remission and improvement of the clinical presentation without evidences of ascites and the CA125 levels were within normal limits.

Discussion

Struma ovarii is characterized by a presence of thy-

Table 1. Review of the cases of ovarian goiter combined with increased levels of CA125 and ascites

Authors	Age of patients (years)	Ascites volume (ml)	Size of tumor (cm)	CA125 (U/ml)	Thyroid disease
Jotkowitz & Gee, 1993 ⁹	79	Not reported	Not reported	4,670	No
Leung & Hammond, 2003 ⁶	60	500	10	224	No
	77	4,000	8 x 10	2,860	
Mancuso et al, 2001 ¹⁰	31	300	10 x 9	689	No
Loizzi et al, 2002 ¹¹	83	3,000	10 x 7 x 6.5	1,570	No
Bokhar et al, 2003 ¹²	51	Not reported	15 x 6.5 x 11	1,160	No
Rim et al, 2005 ¹³	50	3,000	4 x 4	879	No
Guida et al, 2005 ¹⁴	42	4,000	9.1 x 7.7	2,548	Graves' disease
Mui et al, 2009 ³	56	8,210	6 x 5 x 4	5,218	Non - toxic multinodular goiter

roid tissue that occupies more than 50% of the tumor's total mass and it was first described in 1899⁵. The tumor is usually benign, but in rare occasions (5%) we notice a malignant change. Despite the fact that the tumor mainly consists of thyroid tissue, thyrotoxicosis appears only in 5% of the cases. The typical age of appearance is the 5th and 6th decade. It rarely appears before adolescence⁵. The clinical presentation of struma ovarii is similar to the other cancers of the ovary, with no special characteristics. Abdominal pain, palpable abdominal mass, ascites, abnormal vaginal bleeding are the most common symptoms. In rare occasions it could be accompanied by pseudo - Meigs syndrome and clinical hyperthyroidism³. Differential diagnosis must be done from all the ovarian tumors (benign and malignant), ectopic pregnancy, hydrosalpinx, tubo - ovarian abscess. The treatment is surgical and varies according to the age of the patient and the wish to preserve the fertility.

The increase of CA125 combined with ascites can usually be found in cases of malignant epithelial tumors of the ovary and more rarely in cases

of endometrial, colorectal, breast and lung cancer. Moreover, the increase of its levels might accompany situations such as menstruation, pregnancy, endometriosis and ovarian fibroma⁶. The precise mechanism of the increase of the levels of CA125 in the case of struma ovarii is unknown. The probable cause is the inflammation of the peritoneum, the stimulation of the mesothelial cells and, as a result, the increased production of CA125 from its surface⁷. Concerning ascites, there are various speculations, such as the obstruction of the peritoneal lymphatic vessels by the ovarian mass, the inflammatory response of the peritoneal and the increased permeability of the membranes at the surface of the tumor⁸. An ovarian mass combined with increased levels of CA125 and ascites to a woman in menopause usually points to malignant mass. During the review of the literature, eight reports of cases with the stated findings were discovered³. All cases were treated at first as malignant tumors (Table 1).

In our case, a patient with ovarian mass, ascites and increased levels of CA125 is depicted. She was

treated surgically with removal of the tumor and total hysterectomy, with total remission of the ascites and a decrease of the CA125 to normal levels right after the operation that still remains two months later. In conclusion, even though few similar cases are reported in literature, ovarian goiter should be included to the differential diagnosis of adnexal masses that coexist with ascites and increased levels of CA125. ■

References

1. Roth LM, Talerma A. The enigma of struma ovarii. *Pathology* 2007;39:139 - 46.
2. Bal A, Mohan H, Singh SB, Seghal A. Malignant transformation in mature cystic teratoma of the ovary: report of five cases and review of the literature. *Arch Gynecol Obstet* 2007;275:179 - 82.
3. Mui MP, Tam KF, Tam FK, Ngan HY. Coexistence of struma ovarii with marked ascites and elevated CA-125 levels: case report and literature review. *Arch Gynecol Obstet* 2009;279:753 - 7.
4. Yoo SC, Chang KH, Lyu MO, Chang SJ, Ryu HS, Kim HS. Clinical characteristics of struma ovarii. *J Gynecol Oncol* 2008;19:135 - 8.
5. Yassa L, Sadow P, Marqusee E. Malignant struma ovarii. *Nat Clin Pract Endocrinol Metab* 2008;4:469 - 72.
6. Leung YC, Hammond IG. Limitations of CA 125 in preoperative evaluation of a pelvic mass: struma ovarii and ascites. *Aust N Z J Obstet Gynecol* 1993;33:216 - 7.
7. Lin JY, Angel C, Sichel JZ. Meigs syndrome with elevated serum CA125. *Obstet Gynecol* 1992;80:563 - 5.
8. Abad A, Cazorla E, Ruiz F, et al. Meigs syndrome with elevated CA125: case report and review of the literature. *Eur J Obstet Gynecol Reprod Biol* 1999;82:97 - 9.
9. Jotkowitz MW, Gee DC. Unique case of massive ascites, extreme elevation of serum CA125 tumor marker. *Aust N Z J Obstet Gynecol* 1993;33:453 - 4.
10. Mancuso A, Triolo O, Leonardi I, De Vivo A. Struma ovarii: a rare benign pathology which may erroneously suggest malignancy. *Acta Obstet Gynecol Scand* 2001;80:1075 - 6.
11. Loizzi V, Capuccini F, Berma ML. An unusual presentation of struma ovarii mimicking a malignant process. *Obstet Gynecol* 2002;100:1111 - 2.
12. Bokhari A, Rosenfeld GS, Cracchiolo B, Heller DS. Cystic struma ovarii presenting with ascites and an elevated CA125 levels. *J Reprod Med* 2003;48:52 - 6.
13. Rim SY, Kim SM, Choi HS. Struma ovarii showing clinical characteristics of ovarian malignancy. *Int J Gynecol Cancer* 2005;15:1156 - 9.
14. Guida M, Mandato VD, Spiezio Sardo A. Coexistence of Graves' disease and benign Struma ovarian in a patient with marked ascites and elevated CA125 levels. *J Endocrinol Invest* 2005;28:827 - 30.